

Long-term Acyclovir Use to Prevent Recurrent Ocular Herpes Simplex Virus Infection

Uchoandro B. C. Uchoa, MD; Renata A. Rezende, MD; Maria A. Carrasco, MD; Christopher J. Rapuano, MD; Peter R. Laibson, MD; Elisabeth J. Cohen, MD

Objective: To evaluate the effectiveness of more than 12 months of oral acyclovir therapy in reducing recurrences of ocular herpes simplex virus.

Methods: We retrospectively compared ocular herpes simplex virus recurrence in 2 groups of patients. In group 1, patients used oral acyclovir for at least 12 months and then discontinued the treatment. In group 2, patients received the treatment for at least 18 months. We compared recurrences when both groups were using acyclovir (period 1) and when only group 2 was receiving the drug (period 2). Statistical analysis was performed with the *t* test, χ^2 test, and Kaplan-Meier method.

Results: Group 1 had 18 patients and a mean \pm SD follow-up of 45.2 ± 22.2 months. Group 2 had 22 patients and a mean \pm SD follow-up of 42.4 ± 30.2 months. Six patients (33%) in group 1 and 4 patients (18%) in group 2 had recurrence in period 1 ($P = .3$). In period 2, 14 patients (78%) in group 1 and 8 patients (36%) in group 2 had recurrence ($P = .01$). Mean \pm SD recurrence-free survival in period 2 was 15.3 ± 5.5 months in group 1 and 37.3 ± 6.3 months in group 2 ($P = .001$).

Conclusions: Long-term oral acyclovir use seems to remain effective in decreasing the number of ocular herpes simplex virus recurrences beyond 12 months.

Arch Ophthalmol. 2003;121:1702-1704

HERPES SIMPLEX virus (HSV) is a common cause of ocular disease in the United States and around the world. Approximately 400 000 people in the United States have had ocular HSV, and there are about 50 000 new and recurrent cases each year.¹ HSV type 1 causes almost all cases of ocular HSV infection.² The recurrence rate of ocular HSV is approximately 20% within 2 years, 40% within 5 years, and 67% within 7 years.³

Acyclovir is an acyclic purine nucleoside analogue that binds to viral DNA polymerase or acts as terminator of the sugar backbone of DNA, which results in incomplete DNA chains, thus preventing replication of the virus.^{1,4} Results of many articles show that prolonged treatment with oral acyclovir reduces the recurrence rate of genital and labial HSV.⁵⁻⁹ The use of oral acyclovir in ocular HSV has aided in management of this disease and might be the cause of the decrease in penetrating keratoplasties necessitated by HSV.¹⁰ The Herpetic Eye Disease Study demonstrated that prophylactic treatment with oral acyclovir decreases the

number of ocular HSV recurrences during 12 months.^{11,12} Nevertheless, there are few data in the literature regarding the use of acyclovir for more than 12 months. The purpose of this study was to evaluate the use of oral acyclovir for more than 12 months to determine whether it provides additional prevention of ocular HSV recurrence.

METHODS

We retrospectively reviewed medical records in all patients with ocular HSV seen at the Cornea Service at Wills Eye Hospital (Philadelphia, Pa) from January 1, 1996, through December 31, 2001. These patients were identified through a computerized diagnosis code search. We included in the study all patients with recurrent ocular HSV who received 400 mg of oral acyclovir twice a day for at least 12 months. Recurrent disease was defined as 1 or more episodes of ocular HSV (ie, blepharoconjunctivitis, epithelial keratitis, stromal keratitis, or iritis) prior to acyclovir use. Patients who had a corneal transplant or irregular acyclovir use were excluded.

After 12 months of using acyclovir, patients were offered the option to either stop or continue receiving the drug. We generally encouraged patients with more virulent disease,

From the Cornea Service, Wills Eye Hospital, Jefferson Medical College, Thomas Jefferson University, Philadelphia, Pa. The authors have no relevant financial interest in this article.

Table 1. Patient Sex and Age*

Patient Group	No. (%) of Patients		Patient Age, y†
	Male	Female	
Group 1	9 (50)	9 (50)	45.5 ± 20.3
Group 2	12 (54)	10 (46)	57.1 ± 14.7
Total	21 (52)	19 (48)	NA

Abbreviation: NA, not applicable.

*For sex comparison, $P = .75$; for age comparison, $P = .2$.

†Data indicate the mean ± SD.

Table 2. Types of Recurrence in Period 2*

Recurrence Type	Group 1	Group 2	Total
Blepharoconjunctivitis	0	1	1
Epithelial keratitis	5	2	7
Stromal keratitis	8	4	12
Iritis	1	1	2
Total	14	8	22

*Data indicate the number of patients.

such as keratouveitis with inflammatory glaucoma or moderate central scarring, to continue with acyclovir.

Patients were placed in 1 of 2 groups. Group 1 was the control group; patients used acyclovir for at least 12 months (mean ± SD, 16 ± 3.8 months) and then discontinued it. Patients were observed for at least 6 months after the end of the acyclovir treatment. Group 2 had patients who were treated with acyclovir for at least 18 consecutive months and did not discontinue the treatment during follow-up (mean ± SD, 42.4 ± 30.2 months).

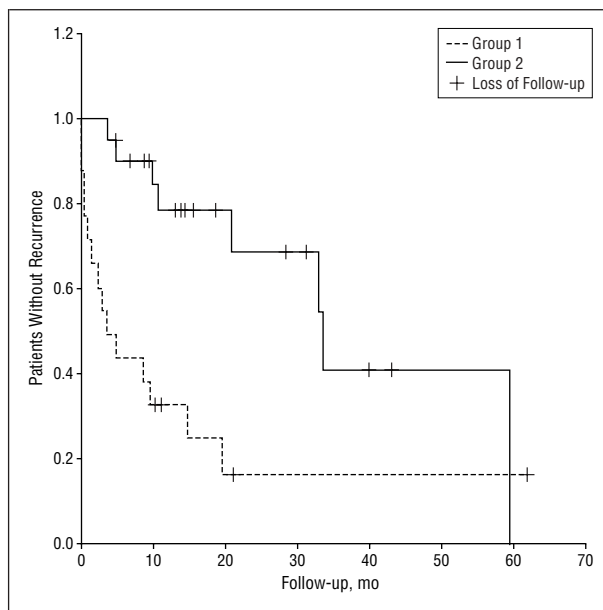
We compared HSV recurrence in both groups during the 2 periods. Recurrences were classified as 1 of the following: blepharoconjunctivitis, epithelial keratitis, stromal keratitis, or iritis.

Statistical analysis was performed by using the Kaplan-Meier method with the purpose of comparing the recurrence-free survival (time to recurrence) between the 2 groups in period 2. The χ^2 test or t test was used to compare the other variables. Statistical significance was indicated by $P < .05$.

RESULTS

Eighteen patients were included in group 1 and 22 patients in group 2. Mean ± SD follow-up was 45.2 ± 22.2 months in group 1 and 42.4 ± 30.2 months in group 2. There was no statistically significant difference in follow-up between the groups ($P = .67$). The demographic characteristics of both groups were similar (Table 1).

Six patients (33%) in group 1 and 4 patients (18%) in group 2 had HSV recurrence during period 1, when both groups were using acyclovir. There was no statistically significant difference in the recurrence rate between the 2 groups during period 1 ($P = .3$). One patient had epithelial keratitis (group 2), and 9 patients had stromal keratitis (6 patients in group 1 and 3 patients in group 2). During period 2, when only group 2 used acyclovir, 14 patients (78%) had ocular HSV recurrence in group 1, and 8 patients (36%) had recurrence in group 2. This



Recurrence-free survival curve in period 2. Mean ± SD recurrence-free survival (time to recurrence) during period 2 was 15.3 ± 5.5 months in group 1 and 37.3 ± 6.3 months in group 2. This difference was statistically significant ($P = .001$). Groups are described in the "Methods" section.

difference was statistically significant ($P = .01$). The types of recurrence are described in Table 2.

Mean ± SD recurrence-free survival (time to recurrence) during period 2 was 15.3 ± 5.5 months in group 1 and 37.3 ± 6.3 months in group 2 (Figure). This difference was statistically significant ($P = .001$).

COMMENT

In this study, we evaluated ocular recurrence of HSV after 12 months of treatment with oral acyclovir. Follow-up was similar in both groups. In the control group (group 1), the patients received acyclovir for at least 12 months and then discontinued treatment. After discontinuation, 78% had HSV recurrence, and the time to recurrence was 15.3 months. In group 2, the patients continued taking acyclovir for more than 12 months. After the first 12 months of treatment, 36% had recurrence, and the time to recurrence was 37.3 months. Rate of recurrence and time to recurrence were both statistically significant between the 2 groups. There was no significant difference between the 2 groups regarding sex, age, and rate of recurrence in period 1, when both groups were using acyclovir.

There are many articles concerning the use of oral acyclovir to prevent recurrence of ocular HSV.^{4,13-16} To our knowledge, the Herpetic Eye Disease Study was the first multicenter, prospective, placebo-controlled clinical trial to determine the benefit of acyclovir in preventing recurrent herpetic eye disease.¹² In the Herpetic Eye Disease Study, the cumulative probability of a recurrence of any type of ocular HSV was 19% in the acyclovir group and 32% in the placebo group ($P < .001$). However, the Herpetic Eye Disease Study analyzed the use of acyclovir for only 12 months, which was followed by 6 months of observation. During this period, there was no

significant difference in the ocular HSV recurrence rate in the 2 groups.¹²

There are few data in the literature regarding the use of oral acyclovir for more than 12 months for ocular purposes. Colin et al¹⁶ and Simon and Pavan-Langston⁴ studied the use of oral acyclovir for more than 12 months for prevention of herpetic keratitis recurrence. Results of both studies showed benefit in prophylactic treatment with acyclovir. However, the authors looked only at epithelial recurrences, and they also included patients who had undergone penetrating keratoplasty.

Lairson et al¹⁷ reported recently that long-term treatment with oral acyclovir is not cost-effective, and the decision to maintain the treatment for a long time must be based on the specific case. We suggest prolonged treatment for patients with virulent HSV-related ocular disease, such as keratouveitis with inflammatory glaucoma or moderate central scarring, in which 1 additional HSV episode could severely affect vision. Additionally, some patients in our study preferred to continue taking acyclovir because the number of episodes of fever blisters decreased.

There are some limitations to our study. It is a retrospective study with a limited number of patients, and there is variability in follow-up. The difference in recurrence rates between group 1 (33%) and group 2 (18%) in period 1 was not statistically significant, but this finding could have been because of the small number of patients. This difference, combined with the fact that the patients had the option to either stop or continue the treatment after 12 months, may have led to a selection bias. Group 1 might have been more likely to discontinue treatment because the drug was less effective for them. Nevertheless, we conclude that the use of oral acyclovir for more than 12 months provides substantial additional prevention against recurrence of ocular HSV. Our data suggest that long-term oral acyclovir use remains effective in decreasing the number of recurrences beyond 12 months. More studies, ideally prospective, are necessary to confirm our results.

Submitted for publication March 6, 2003; final revision received June 27, 2003; accepted July 2, 2003.

Corresponding author: Elisabeth J. Cohen, MD, Cornea Service, Wills Eye Hospital, 840 Walnut St, Suite 920, Philadelphia, PA 19107 (e-mail: ecohen@willseye.org).

REFERENCES

1. Kaufman HE. Can we prevent recurrences of herpes infections without antiviral drugs? The Weisenfeld Lecture. *Invest Ophthalmol Vis Sci.* 2002;43:1325-1329.
2. Neumann-Haefelin D, Sundmacher R, Wochnik G, Bablok B. Herpes simplex virus types 1 and 2 in ocular disease. *Arch Ophthalmol.* 1978;96:64-69.
3. Liesegang TJ. Herpes simplex virus epidemiology and ocular importance. *Cornea.* 2001;20:1-13.
4. Simon AL, Pavan-Langston D. Long-term oral acyclovir therapy: effect on recurrent infectious herpes simplex keratitis in patients with and without grafts. *Ophthalmology.* 1996;103:1399-1404.
5. Mertz GJ, Eron L, Kaufman R, et al. Prolonged continuous versus intermittent oral acyclovir treatment in normal adults with frequently recurring genital herpes simplex virus infection. *Am J Med.* 1988;85:14-19.
6. Mertz GJ, Jones CC, Mills J, et al. Long-term acyclovir suppression of frequently recurring genital herpes simplex virus infection: a multicenter double-blind trial. *JAMA.* 1988;260:201-206.
7. Spruance SL. Prophylactic chemotherapy with acyclovir for recurrent herpes simplex labialis. *J Med Virol.* 1993;suppl 1:27-32.
8. Kaplowitz LG, Baker D, Gelb L, et al. Prolonged continuous acyclovir treatment of normal adults with frequently recurring genital herpes simplex virus infection: the Acyclovir Study Group. *JAMA.* 1991;265:747-751.
9. Goldberg LH, Kaufman R, Kurtz TO, et al. Long-term suppression of recurrent genital herpes with acyclovir: a 5-year benchmark: Acyclovir Study Group. *Arch Dermatol.* 1993;129:582-587.
10. Cosar CB, Sridhar MS, Cohen EJ, et al. Indications for penetrating keratoplasty and associated procedures, 1996-2000. *Cornea.* 2002;21:148-151.
11. Herpetic Eye Disease Study Group. Oral acyclovir for herpes simplex virus eye disease: effect on prevention of epithelial keratitis and stromal keratitis. *Arch Ophthalmol.* 2000;118:1030-1036.
12. Herpetic Eye Disease Study Group. Acyclovir for the prevention of recurrent herpes simplex virus eye disease. *N Engl J Med.* 1998;339:300-306.
13. Tambasco FP, Cohen EJ, Nguyen LH, et al. Oral acyclovir after penetrating keratoplasty for herpes simplex keratitis. *Arch Ophthalmol.* 1999;117:445-449.
14. Akova YA, Onat M, Duman S. Efficacy of low-dose and long-term oral acyclovir therapy after penetrating keratoplasty for herpes simplex keratitis. *Ocul Immunol Inflamm.* 1999;7:51-60.
15. Barney NP, Foster CS. A prospective randomized trial of oral acyclovir after penetrating keratoplasty for herpes simplex keratitis. *Cornea.* 1994;13:232-236.
16. Colin J, Robinet A, Malet F. Preventive treatment of herpetic keratitis with acyclovir tablets [in French]. *J Fr Ophthalmol.* 1993;16:6-9.
17. Lairson DR, Begley CE, Reynolds TF, et al. Prevention of herpes simplex virus eye disease: a cost-effectiveness analysis. *Arch Ophthalmol.* 2003;121:108-112.

Notice to Authors: Submission of Manuscripts

Selected manuscripts submitted to the *Archives of Ophthalmology* will be submitted for electronic peer review. Please enclose a diskette with your submission containing the following information:

File name
Make of computer
Model number
Operating system
Word processing program and version number